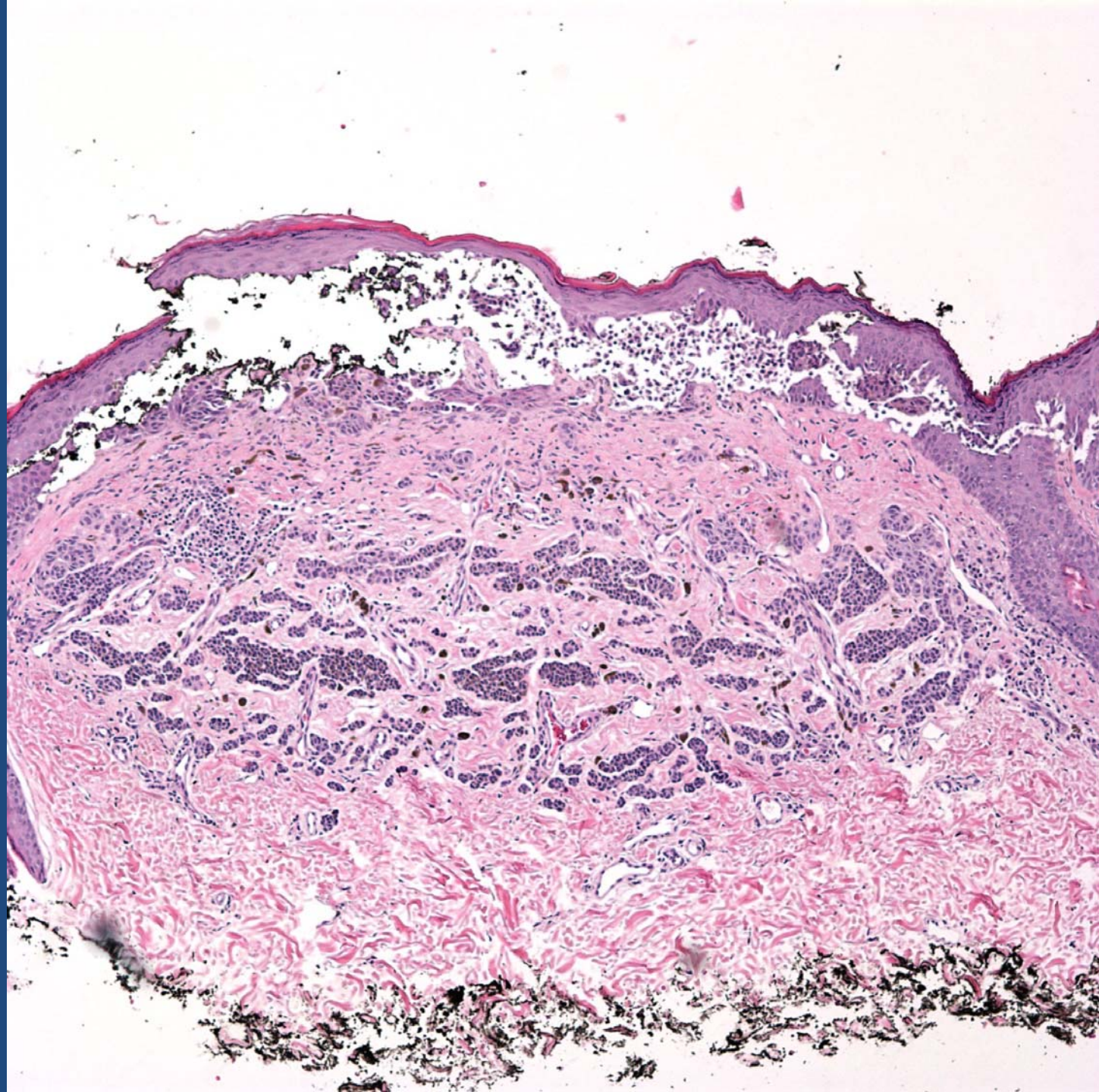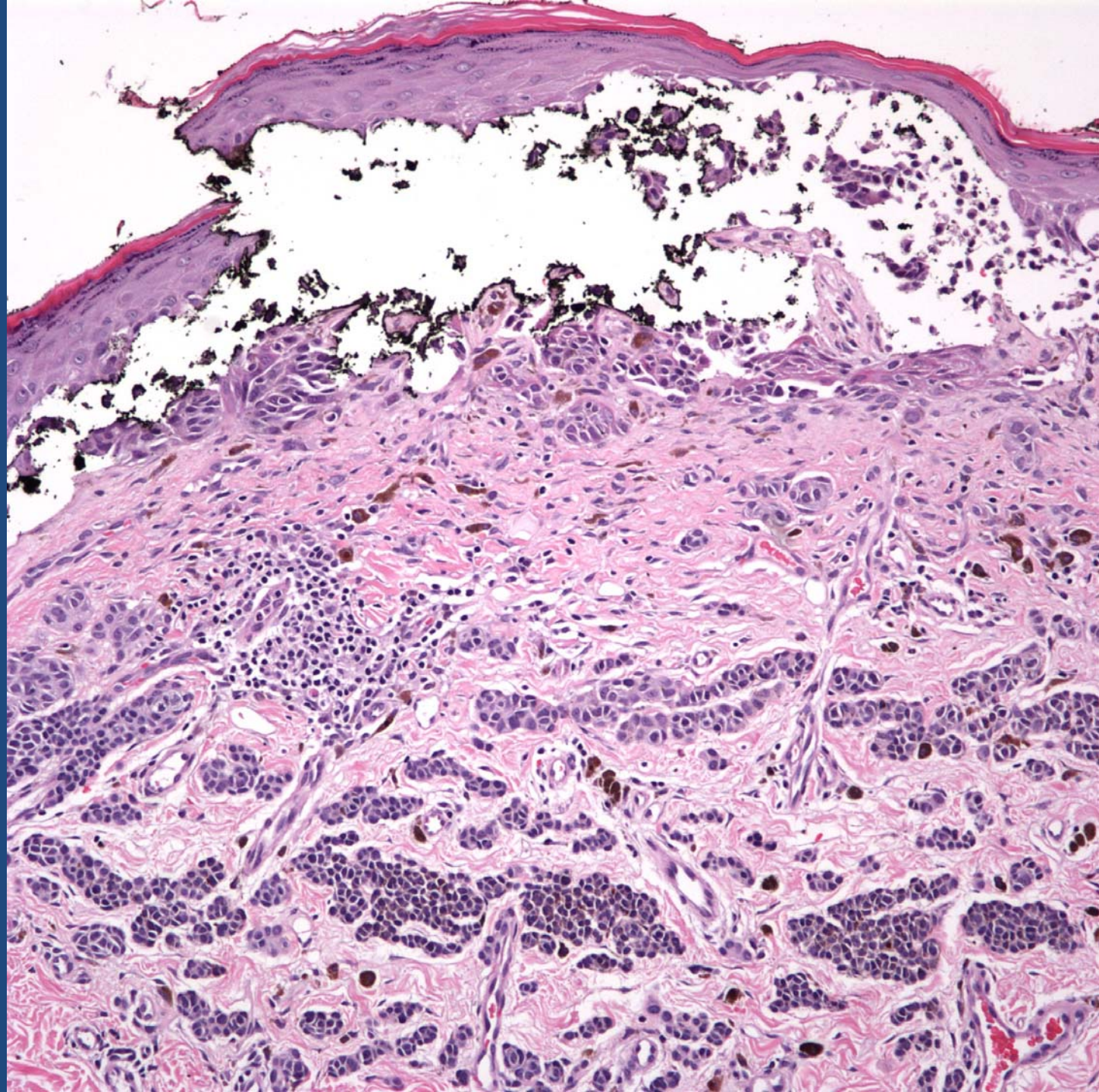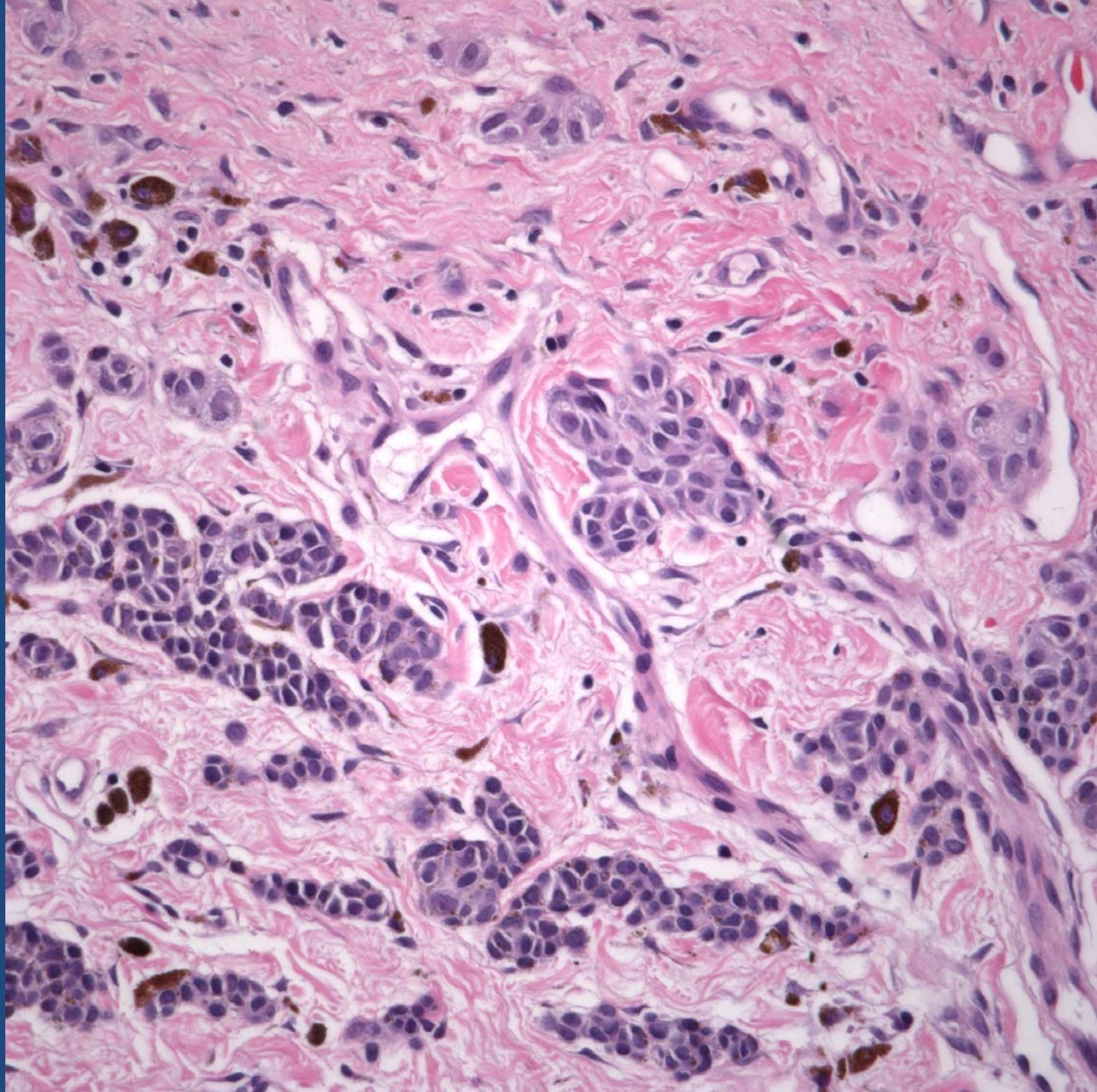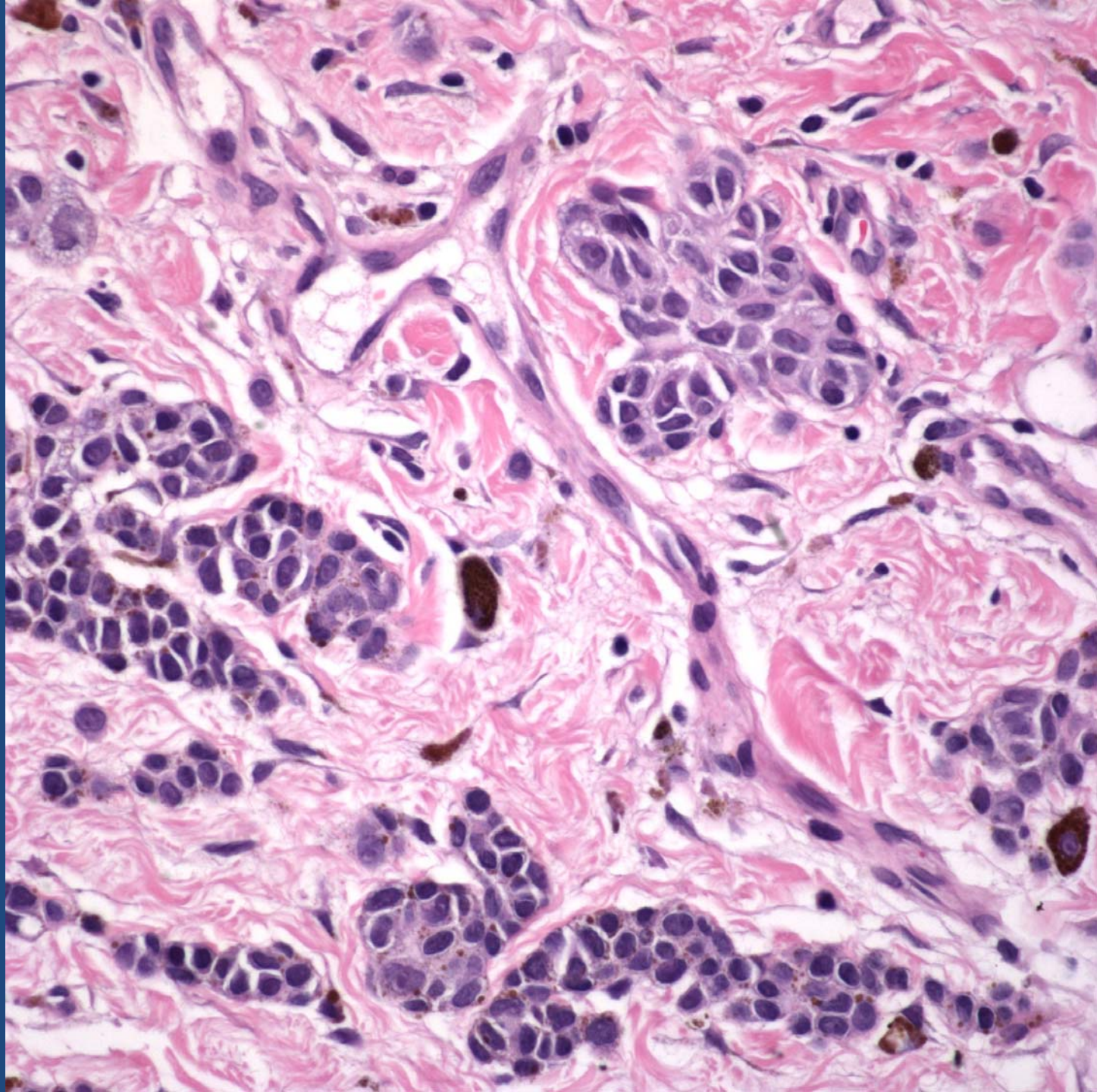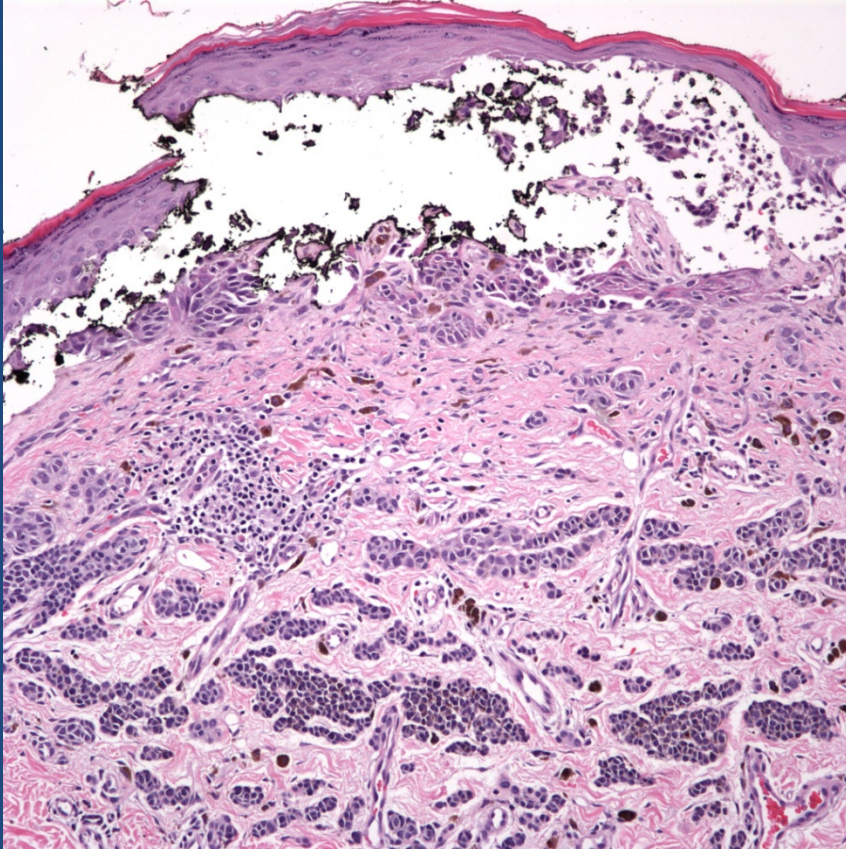


Malignant Melanoma

Pearls



- Dyscohesive clefting by expansile nest of cytologically malignant melanocytes may mimic a bullous lesion
- Measure from either the base of the detachment in the dermis or intact epidermis (granular layer)
- Disclaimer may be needed to explain variation in measurement